

Chapter 17

RADIOLOGY IN EMERGENCIES

Learning Objectives:

At the end of the session, participants should be able to:

- Interpret emergency chest radiographs in a systematic manner.
- Recognize immediate life-threatening injuries in the thorax (lethal six).
- Recognize potential life-threatening injuries in the thorax (hidden six).
- Independently perform Focused Assessment with Sonography in Trauma (FAST).
- Interpret emergency cervical spine radiographs in a systematic manner.

INTRODUCTION

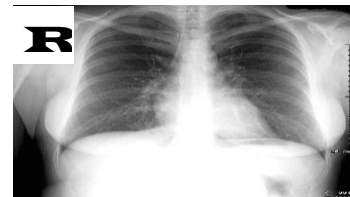
Diagnostic Imaging plays a minor part in the ATLS course. Yet with imaging in emergencies, one is able to identify life threatening and potentially life-threatening injuries on chest radiographs, identify fractures on radiographs of the spine and can direct treatment decisions. Imaging should be performed in the primary survey when indicated.

Adjuncts to the primary survey include: radiographs of the Chest, Pelvis, Cervical spine and FAST (Focused Assessment with Sonography in Trauma). Imaging is considered helpful but should be used judiciously and should not interrupt or delay the resuscitation process. When appropriate, radiography may be postponed until the secondary survey. CT, contrast studies and radiographs of the spine and extremities are adjuncts to the secondary survey.

NORMAL CHEST X-RAY INTERPRETATION

Identification:

Every X-ray should include patient demographics (Name, age, gender), X-ray number, date of x-ray, and markers (R/L) for the purpose of identification.



Orientation:

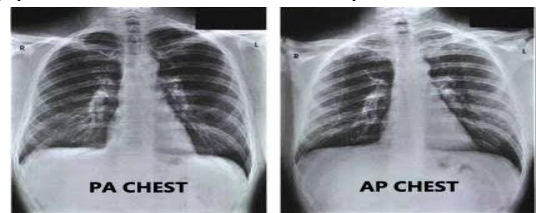
Reference to position of patient and X-ray beam. **Posterior-**

Anterior (PA) radiograph: X-ray traversing patient from posterior to anterior and striking film.

Antero-Posterior (AP) radiograph: X-ray traversing patient from anterior to posterior and striking film.

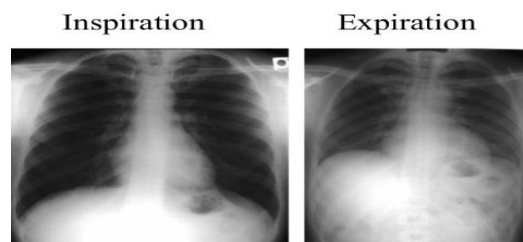
Cardiac border will appear larger on:

- AP radiograph due to magnification effect of more anteriorly located heart relative to the film.
- expiratory film
- supine film
- short focus to film distance (FFD).



Inspiration:

Volume of air in the hemithorax affects the configuration of the heart in relation to cardiac size. Vascular pattern in lung fields will be accentuated with shallow inspiration. The level of inspiration can be estimated by counting ribs. Visualization of 10 posterior ribs or 6 anterior ribs on upright PA X-ray projecting above the diaphragm would indicate a satisfactory inspiration.

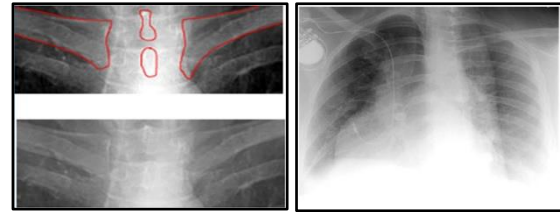


Penetration:

Refers to adequate X-ray photons traversing the patient to expose the radiograph. Lack of penetration renders the area "whiter" than with an adequate film and can simulate pneumonia or effusion. In an ideal radiograph, the thoracic spine should be barely visible through the cardiac shadow, the Lt hemidiaphragm behind the heart and vessels up to 2/3 of lung area.

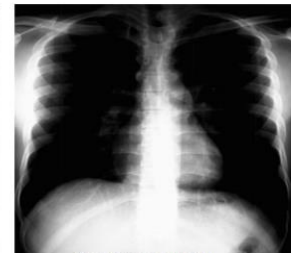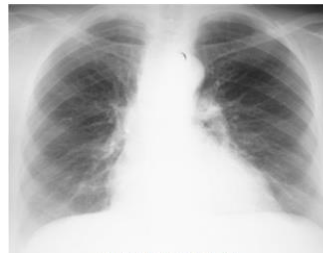
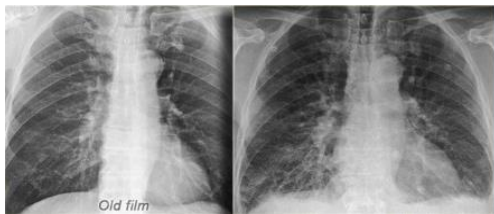Rotation:

Ideally medial ends of clavicles should be equidistant from thoracic spinous processes. Rotation of patient distorts mediastinal anatomy and makes assessment of cardiac chambers and hilar structures difficult.



Comparison:

Whenever prior X-rays are available, comparisons should be made in order to assess progress or deterioration in the condition of the patient. Comparison X rays are also taken in pre and post procedure settings.

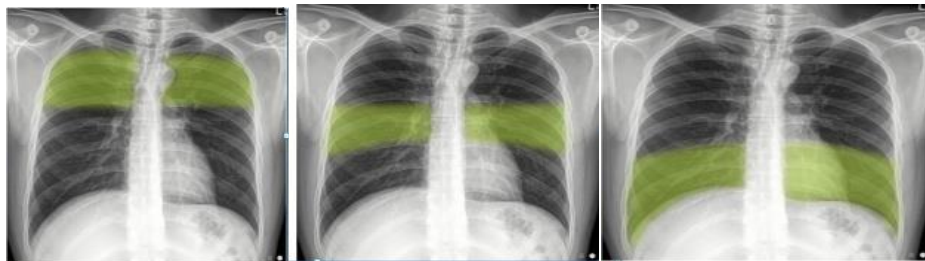

Lung zones:

Upper zone: lungs below clavicles and above cardiac silhouette, above first 2 ribs

Mid zone: lungs at level of hilar structures, between 2nd and 4th ribs.

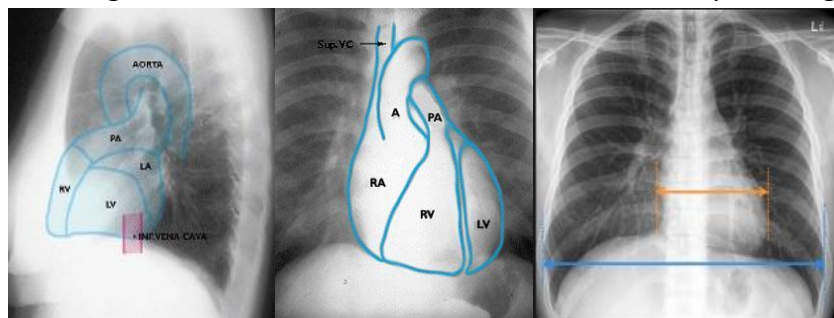
Lower zone: lungs below 4th ribs.



Great vessels and heart:

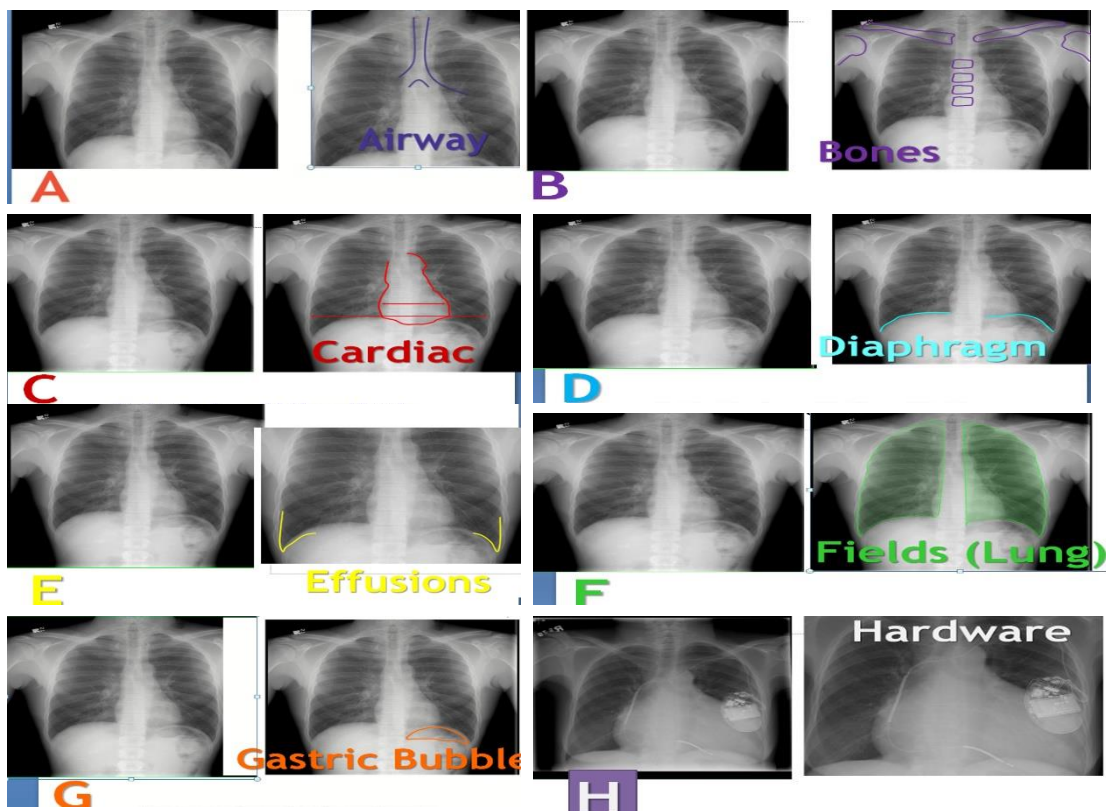
Two third of cardiac shadow should be seen to the left of midline. Right cardiac border is formed by right atrium. Left cardiac by left atrium and left ventricle. Superior mediastinum is formed by ascending aorta and SVC on the right and the aortic arch, descending aorta and pulmonary bay on the left side.

Cardiac size is measured by drawing vertical parallel lines down the most lateral points on each side of the heart, and measuring between them. Thoracic width is measured by drawing vertical parallel lines down the inner aspect of the widest points of the rib cage, measuring distance between them. Normal cardio-thoracic ratio (CTR) <50 % on PA film.



ABC APPROACH

Airway, Bones, Cardiac, Diaphragm, Effusions, Fields (lungs), Gastric bubble, Hardware.

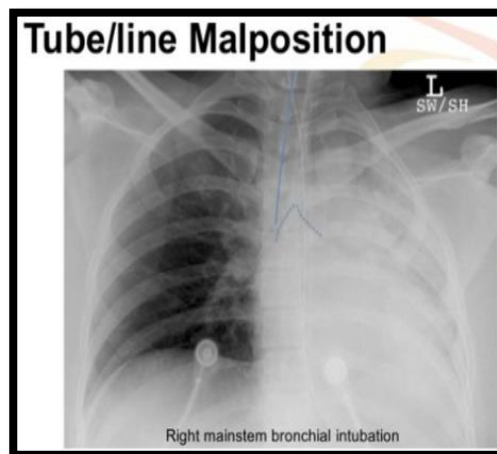
**PORTABLE TRAUMA CHEST X-RAY**

Imaging survey should include:

Tube/line malposition:

Lines and tubes are important components in chest radiographic evaluation.

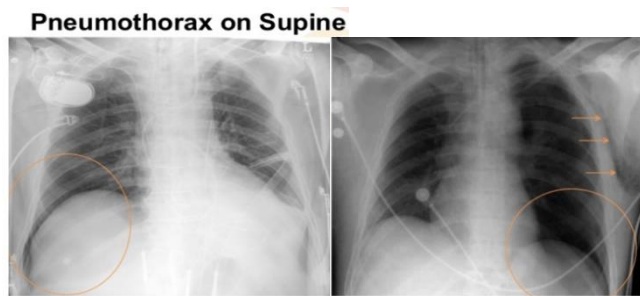- Insertion of NG tube into trachea or bronchus will cause pneumonia, pulmonary contusion, and pulmonary laceration. Insertion of NG tube can also cause pharyngeal or esophageal perforation.
- Selective intubation of ET can cause contralateral lung collapse, hyperinflation of ipsilateral lung and pneumothorax.
- Insertion of central lines into right atrium or ventricle may cause bacterial thrombotic endocarditis, dysrhythmias, myocardial perforation, mediastinal hematoma secondary to vessel perforation, pneumothorax, hemothorax, central line-associated bloodstream infection, deep venous thrombosis.
- Check for placement of intercostal tube or catheter into lung parenchyma, interlobar fissure or subcutaneous tissue. Malplaced intercostal catheter may also result in mediastinal or abdominal visceral trauma.



Large pneumothorax: Supine Chest X-ray:

- deep sulcus sign - a very wide and deep CP angle.
- hyperexpanded hemithorax,
- increased lucency.
- increased sharpness of heart border.
- subcutaneous emphysema.

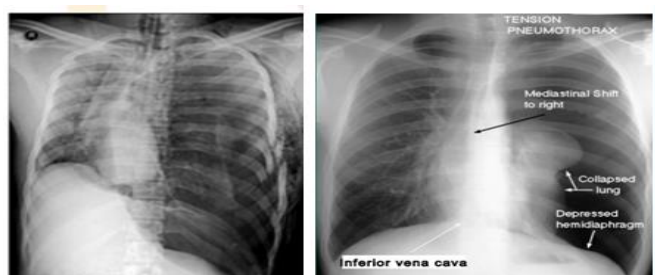
Open pneumothorax: pleural cavity communicates with the atmosphere, leading to total lung collapse on affected side.



Closed pneumothorax: No communication of the pleural cavity to the atmosphere. Trachea may be central or slightly shifted towards the healthy side.

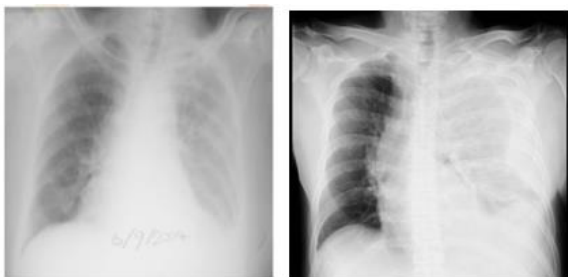
Classic signs of Tension pneumothorax:

- deviation of trachea away from the side with tension,
- shift of the mediastinum,
- hyper-expanded chest,
- depression of hemidiaphragm,
- Widened intercostal spaces on affected side.



Can be insidious, especially in mechanical ventilation. Tension pneumothorax may also persist if there is injury to a major airway, resulting in a bronchopleural fistula. The patient can also have bilateral tension pneumothoraxes wherein chest X-ray shows trachea is central, with characteristic apparent “disappearance of the heart”.

Hemothorax:

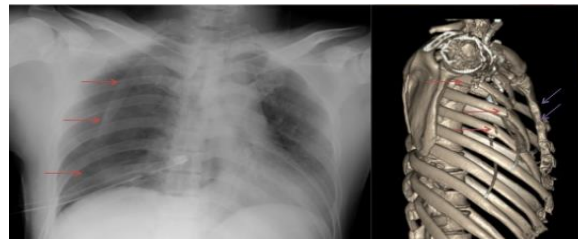


In the acute trauma setting, the portable supine chest radiograph may be the first and only view available from which to make definitive decisions regarding therapy. The presence and size of hemothorax is much more difficult to evaluate on supine films. At least 175-500 mL of blood is required to obliterate the lateral costo-phrenic angle on

an upright chest radiograph, as much as 1000 mL of blood may be missed when viewing a portable supine film. Only a general haziness of affected hemithorax may be noted. In blunt trauma cases, hemothorax is frequently associated with other chest injuries visible on the chest radiograph, such as rib fractures, pneumothorax, or widening of the superior mediastinum.

Flail chest:

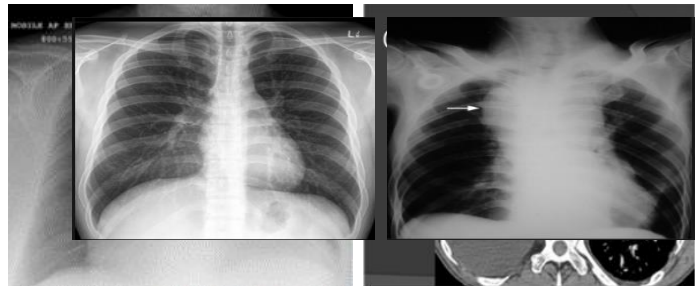It is a serious, life threatening chest injury, most commonly seen in cases of significant blunt trauma. Multiple adjacent ribs are broken in multiple places, leading to instability to a segment of the thoracic wall that exhibits paradoxical motion locally. Often associated with underlying pulmonary injury.



Complications include pneumothorax, hemothorax, lung contusions, and respiratory insufficiency.

Hemopericardium and Cardiac tamponade:

Accumulation of >150ml of blood in the pericardium can cause life threatening tamponade. Chest X-ray is not diagnostic. May see water bottle shaped heart or air fluid level. Echocardiography is diagnostic tool of choice.

**Mediastinal widening:**

Suspect vascular injury if mediastinal width of >8 cm in the AP film with obliterated aortic knob, rightward deviation of trachea, depression of Lt main bronchus, pleural/apical cap, Lt hemothorax, fractures of the 1st/and or 2nd ribs.

Other important findings that may be seen are:

Pneumomediastinum, subcutaneous emphysema, pneumopericardium, air around the pulmonary artery and aorta, continuous diaphragm sign, angel wing sign in neonates.

Diaphragm injury: look for visualization of stomach or other abdominal organs in the chest, elevation of the diaphragm, lack of clarity of diaphragm, abnormal positioning of NG tube, hemothorax, basilar atelectasis.

Unstable spine fractures: Fractures of 1st three ribs are seen in major trauma. Fractures of 4th to 9th ribs are common (thin and poorly protected). Fractures to lower ribs (8th-10th) are associated with renal, hepatic and splenic injuries.

SYSTEMIC EVALUATION OF BLUNT THORACIC TRAUMA

Life threatening Chest Injuries- the Deadly Dozen.

Immediate Life-threatening injuries

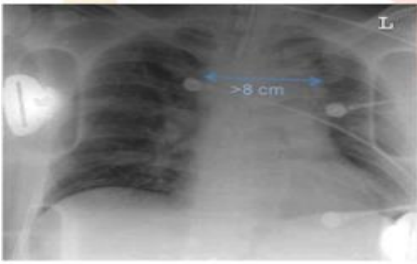
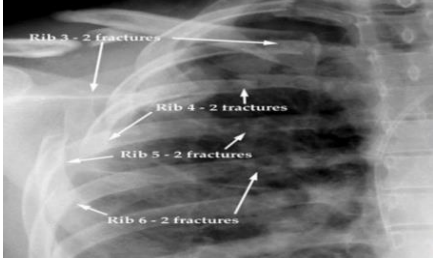



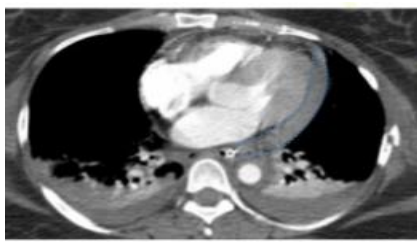


- Air way obstruction
- Tension pneumothorax
- Cardiac injury or pericardial tamponade
- Massive hemothorax
- Open pneumothorax
- Tracheo-bronchial injury

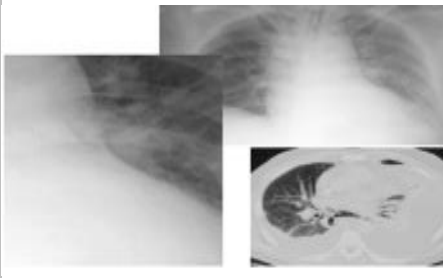
Potentially Life-threatening injuries

- Aortic rupture
- Myocardial injury

- Diaphragm tear
- Esophageal injury
- Pulmonary contusions/lacerations
- Flail chest

ABC approach: Aortic transection, Bronchial trauma, Cord injury, Diaphragm rupture, Esophageal tear, Flail chest, Gas (pneumothorax), Heart injury, Iatrogenic misplaced tubes and catheters.

<p>Aortic transection</p> 	<p>Flail chest</p> 
<p>Bronchial trauma</p> 	<p>Gas (pneumo-thorax)</p> 
<p>Cord injury</p> 	<p>Heart injury</p> 
<p>Diaphragm rupture</p> 	<p>Iatrogenic misplaced tubes & catheters</p> 

Esophageal tear

SYSTEMATIC EVALUATION OF THE CERVICAL SPINE

Clinical considerations are particularly important because:

- normal cervical spine X-rays cannot exclude significant injury
- a missed cervical spine fracture can lead to death
- lifelong neurologic deficit

Imaging should not delay resuscitation.

Cervical spine radiographs

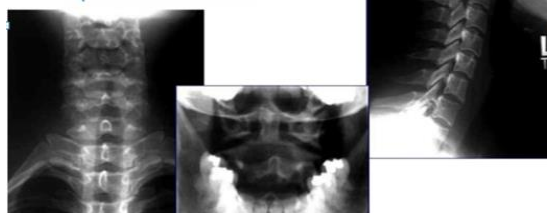Standard Views:

- AP view
- Lateral view
- Odontoid (open mouth view)

Extended View:

- Swimmer view, when lateral radiograph fails to show C7-T1 level

- At least **three views** are recommended for alert and stable trauma patients:
 - anteroposterior view
 - cross-table lateral view
 - open-mouth dens view



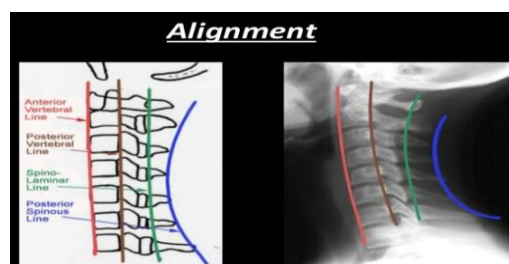
Cervical Spine Systemic Approach: Lateral view

Coverage, Alignment, Bones, Spacing, Soft tissues, Edge of image

Coverage: All vertebrae visible from the skull base to top of T1. If T1 is not visualized, then do Swimmer view.

Alignment: Check:

- Line of anterior longitudinal ligament
- Line of posterior longitudinal ligament
- Spinolaminar line formed by anterior edge of spinous processes
- Posterior spinous process line



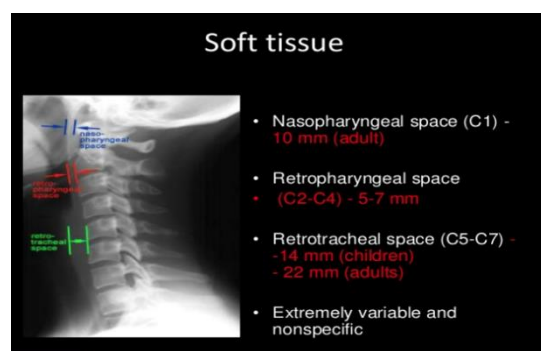
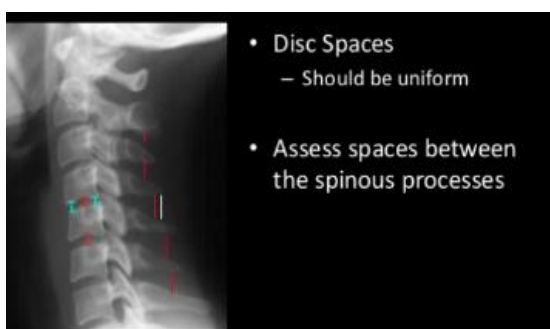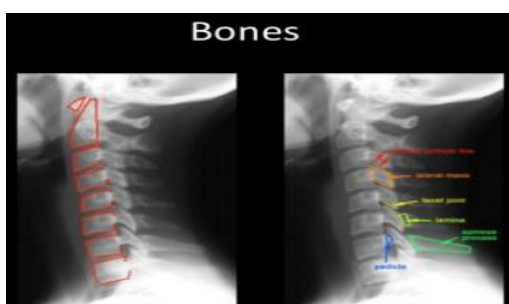Bone: Trace the cortical outline.

Disc Spaces: should be approximately equal in height.

Prevertebral soft tissue: some fractures cause widening of the prevertebral soft tissue due to hematoma. **Normal prevertebral soft tissue:**

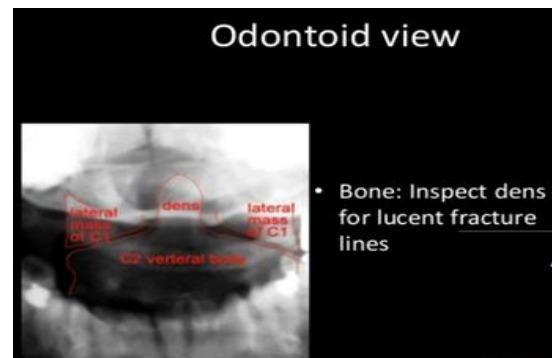
- Above C4 \leq 1/3 vertebral body width
- Below C4 \leq 100% vertebral width

Edge of image: Check other visible structures.



Systematic Approach of Normal AP view

- Coverage: Should cover whole cervical spine and upper thoracic spine
- Alignment: Lateral edges of the spine should be aligned
- Bone: Fractures are often less clearly visible on this view than on the lateral view
- Spacing: Spinous processes are in a straight line and spaced approximately evenly
- Soft tissues: Check for surgical emphysema
- Edges of images: Check for injury to the upper lungs, lung apices for pneumothorax

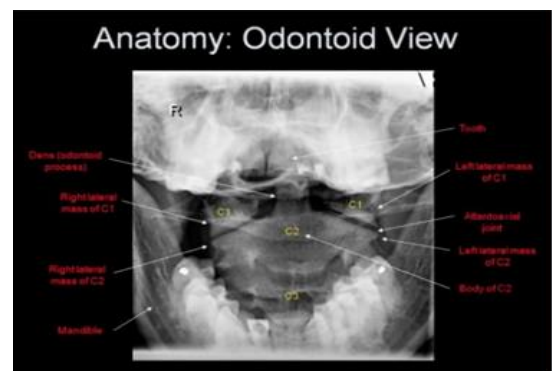


Cervical spine: Open mouth view

This view shows the alignment of the lateral processes of C1 and C2. Distance between the odontoid peg and the lateral masses of C1 should be equal on each side.

The Odontoid view is unreliable in intubated patients. Clinical examination is impossible in unconscious patient.

Plain film radiology cannot exclude ligamentous instability.

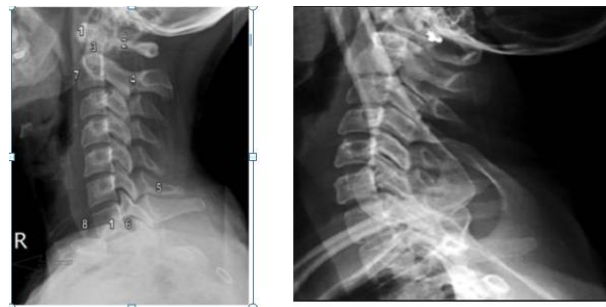

Cervical spine: Swimmer view

This is an oblique view which projects humeral heads away from the cervical spine. Used in assessing alignment at the cervico-thoracic junction, if C7/T1 has not been adequately viewed on the lateral image, or on a repeated lateral image with the shoulders lowered.

Four basic reasons why cervical spine fractures are missed by physicians:

1. Failure to obtain indicated films
2. Inadequate films
3. Misinterpretation of the films
4. Films fail to adequately visualize the injuries.



FOCUSED ASSESSMENT OF ULTRASONOGRAPHY IN TRAUMA

FAST (Focused Assessment with Sonography in Trauma) examination is a focused, goal directed sonographic examination of the abdomen. The goal is to detect presence of hemoperitoneum or hemopericardium. It is an extension of clinical examination and part of the Primary Survey of any patient with signs of shock or suspicion of abdominal injury. FAST is not a definitive diagnostic investigation nor a substitute for CT. Initially focused on identifying free intraperitoneal or pericardial fluid in blunt trauma patients. Now, the use of ultrasound (USG) in trauma has expanded to identifying a variety of traumatic injuries: hemoperitoneum, pneumothorax, hemothorax, hemopericardium with or without tamponade, traumatic hypovolemia, and even rib, nose, and other fractures. FAST is included

in the Advanced Trauma Life Support program for rapid triage of hemodynamically unstable trauma patients for definitive intervention.

Free fluid usually appears anechoic on Ultrasound. It accumulates in the area of injury and overflows into dependent areas (pouch of Douglas), Morrisons pouch) via paracolic gutters and into the thoracic cavity.

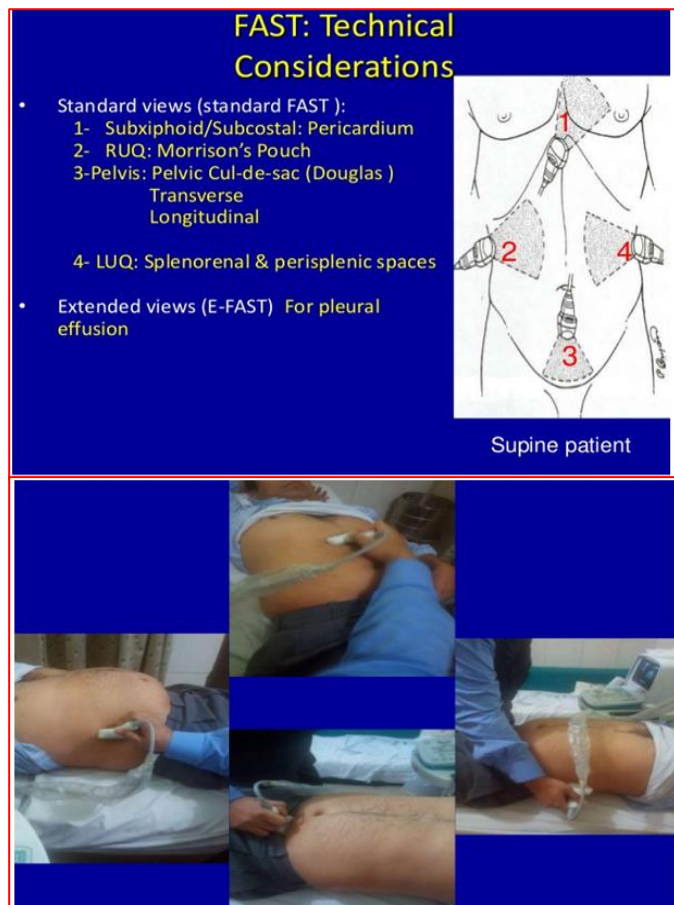
Probe selection in the evaluation of the trauma patient is dependent on what is the main focus of the examination. A sector probe (3–5 MHz) is best utilized as a multipurpose probe. It is appropriate for examining solid organs, determining presence of free fluid in the abdomen or pelvis, to examine the heart for a pericardial effusion or hemorrhage, to scan between the ribs for pneumothorax.

A curved-array transducer may be used in the abdomen for better resolution but is not ideal for imaging of the heart or lung, especially when scanning in the intercostal spaces. Linear-array transducers are not ideal because of their larger footprint in the abdomen and chest and often are of higher frequency with limited depth penetration.

The linear-array transducer probe is placed parallel to the ribs in the intercostal space for detection of pneumothorax.

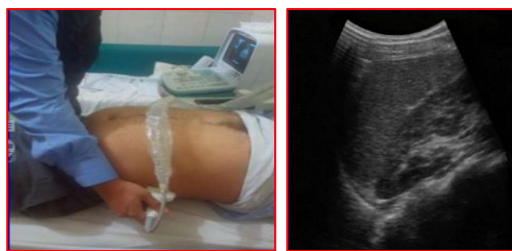The addition of US evaluation of the thorax to detect pneumothorax to the traditional FAST examination resulted in extended FAST (eFAST). There are several other protocols developed for evaluation of shock, respiratory distress, and cardiac arrest, some of which feature echocardiography. Other protocols for evaluation of dyspnea include BLUE (bedside lung US in emergency) and RADIUS (rapid assessment of dyspnea with Ultrasound). The BLUE protocol includes only lung ultrasound for detection of pneumothoraxes, as well as pulmonary edema, consolidation, and effusion. The RADIUS protocol is similar but includes cardiac and inferior vena cava (IVC) evaluation. FAST is portable, rapid, non-invasive, repeatable and cost effective.

- Minimum amount of fluid in abdomen detectable by USG-200 to 650 ml.
- High sensitivity in detecting hemoperitoneum (63-100%).
- High specificity in detecting hemoperitoneum (96-99%).
- Low sensitivity in detecting organ specific lesions (<50%).

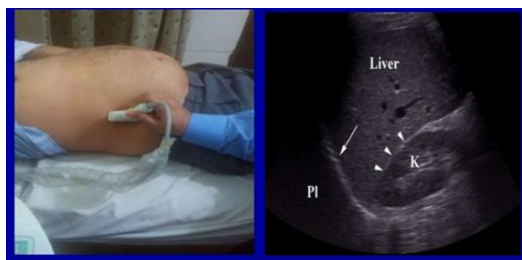

FAST: Right Upper Quadrant (RUQ) exam

In the supine patient, the hepato-renal pouch (Morrison's pouch) is the most dependent space. This view is used for evaluating the hepato-renal interfaces and possibility of fluid in Morrison's pouch. The probe is placed perpendicularly in the mid coronal plane, just superior to the iliac crest. The probe should be directed towards the patient's head.



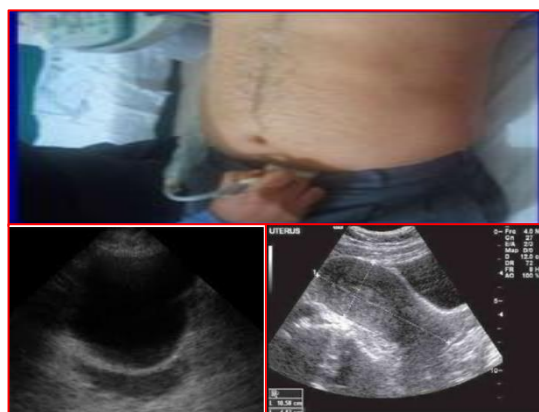FAST: Left Upper Quadrant (LUQ) view



This space is more difficult to evaluate than the RUQ as there is no liver to act as acoustic window. This view is used for evaluating the spleno-renal interfaces and possibility of fluid in the spleno-renal recess and presplenic/subphrenic space. The ultrasound probe is placed perpendicularly, in the mid coronal plane, just superior to the iliac crest. The probe should be directed towards the patient.

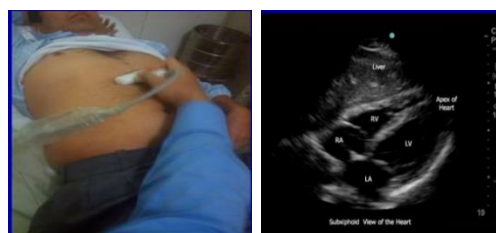FAST: Pelvic exam

In the erect patient, the pouch of Douglas in females and recto-vesical space in males is the most dependent space. View used to evaluate the urinary bladder, uterus in females and the prostate in males, best with some urine in the urinary bladder that acts as acoustic window. The pelvis is scanned in the longitudinal and transverse axes. The probe is placed transversely first and then longitudinally, in the midline 2cm superiorly to the symphysis pubis. For the prostate, the probe is aimed caudally into the pelvis. The ultrasound probe is directed towards the patient's head and Rt side.

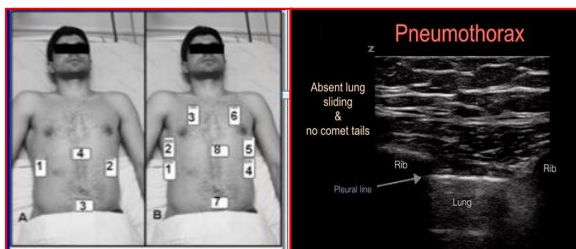


FAST: Subxiphoid exam

This view screens for fluid between the fibrous pericardium and the heart. The ultrasound probe is placed to the left of the xiphisternum and angled upwards under the costal margin.



Extended FAST (eFAST)



RUQ, LUQ views: Check above diaphragm for hemothorax. Ultrasound is superior to chest X-ray for detection of hemothorax. Ultrasound can detect 20 cc or less of fluid against 50-175 cc of fluid required for detection on chest X-ray.

Suprapubic view: used to rule out pregnancy.

FAST Reliability:

Accuracy 86-97%

Sensitivity 88-91.7 %

Specificity 94.7-99%

Interpretation of FAST

- Positive FAST if fluid is detected in pericardium or any of the 4 abdominal windows.
- Negative FAST if there is no fluid detected in any of the 4 abdominal windows.
- Indeterminate FAST if any of the 4 abdominal windows is inadequately visualized.

Advantages of FAST

- Advantages: FAST provides easy and early diagnosis in the Emergency room.
- It is rapid and can be performed within 1-2.5 minutes.
- The study can be repeated, non-invasive and not expensive.

Disadvantages of FAST

- FAST is operator dependent.
- It is difficult to distinguish type of fluid, site of bleeding and solid organ injury by FAST.
- Scanning is difficult in obese patients, in the presence of subcutaneous emphysema and where there is bowel gas interposition.
- FAST cannot evaluate the retroperitoneum and hollow viscus injury adequately.

Sonographic PITFALLS

1. Free fluid in pelvis will often be missed without a full bladder.
2. Sonography can miss important organ injury that will require surgery. USG used to triage unstable patients. CT indicated if intra-abdominal injury is suspected.
3. Sonography is limited or unable to show certain types of injuries:
 - spinal and pelvic fractures
 - diaphragmatic rupture
 - vascular injuries
 - pancreatic injuries
 - adrenal injuries
 - some bowel and mesenteric injuries

References

1. Henry, S., ATLS 10th edition offers new insights into managing trauma patients.
2. Raby, N., Berman, L. and De Lacey, G., 1995. *Accident and Emergency Radiology: A survival guide*. London: WB Saunders.
3. Rippey, J.C. and Royse, A.G., 2009. Ultrasound in trauma. *Best Practice & Research Clinical Anaesthesiology*, 23(3), pp.343-362.
4. Rumack, C.M., Wilson, S., Charboneau, J.W. and Levine, D., 2010. Diagnostic Ultrasound: 2-Volume Set. *Missouri: Elsevier Mosby*.
5. Singh, H. and Neutze, J.A., 2012. Imaging the Trauma Patient. In *Radiology Fundamentals* (pp. 211-217). Springer, New York, NY.
6. Stark, P. and Jacobson, F., 1992. Radiology of thoracic trauma. *Current opinion in radiology*, 4(5), pp.87-93.
7. Sutton, D., 1987. A textbook of radiology and imaging.
8. Whitley, A.S., Jefferson, G., Sloane, C. and Hoadley, G., 2005.
9. *Clark's Positioning in Radiography 12Ed.* crc Press.