

## Chapter 13

# OCULAR TRAUMA AND OCULAR EMERGENCIES

### Learning Objectives:

- Recognizing traumatic and non-traumatic ocular emergencies
- Management of ocular emergencies
- Timely referral to higher center

## INTRODUCTION

Emergencies in ophthalmology can be of various kinds ranging from trauma cases to acute eye inflammations. Ocular trauma is an important cause of visual loss and disability. Early and appropriate management can reduce morbidity and complications. In Birmingham Eye Trauma Terminology System and Ocular Trauma Classification Group have classified traumatic ocular injury into open and closed globe injury. The non-mechanical injuries like ocular burns was classified by Ballen and later modified by Roper Hall to give prognostic guide lines.

### Ocular emergencies can be divided into:

- **Acute emergency** – must be treated within minutes. e.g., chemical burns of the cornea and the conjunctiva.
- **An urgent case** – must be treated within hours. e.g., penetrating globe injuries, corneal abrasions, corneal foreign bodies, hyphemas, eyelid lacerations that are deep, radiant energy burns snow blindness, welder’s burns, and traumatic optic neuropathy.
- **Semi urgent case** – must be managed within 1 to 2 days. e.g., orbital fractures, sub-conjunctival hemorrhages.

## COMMON OCULAR EMERGENCIES

- Chemical burn
- Ocular trauma-
  - Penetrating trauma and ruptured globe.
  - Non-penetrating trauma- abrasions, foreign bodies, lacerations, hyphemas, blow out fractures.
- Others:
  - acute conjunctivitis.
  - Glaucoma.
  - Orbital cellulitis.

## CHEMICAL BURN

Chemical exposures and burns are usually caused by a splash of liquid but can also be caused by transferring a chemical from your hands to your eyes by rubbing or by being sprayed by aerosols. Treatment should be instituted IMMEDIATELY, even before testing vision, unless an open globe is suspected.

*Note:* This includes alkali (e.g., lye, cements, plaster, airbag powder) acids, solvents, detergents, and irritants (e.g., mace). Alkalis cause more damage as they cause saponification and can penetrate deeper.

**Signs-** redness, watering, light sensitivity, pain, decreased vision.

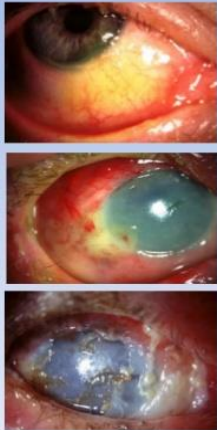
**Symptoms-** corneal haze, congestion or blanching at limbus, raised intraocular pressure.

### Emergency Treatment:

- Copious irrigation using saline or Ringer lactate solution for at least 30 minutes. Tap water can be used in the absence of these solutions. An eyelid speculum and topical anesthesia can be placed prior to irrigation. Upper and lower fornices must be everted and irrigated. Manual use of intravenous tubing connected to an irrigation solution facilitates the irrigation process.
- Conjunctival fornices should be swept with a moistened cotton-tipped applicator or glass rod to remove any sequestered particles of caustic material and necrotic conjunctiva.

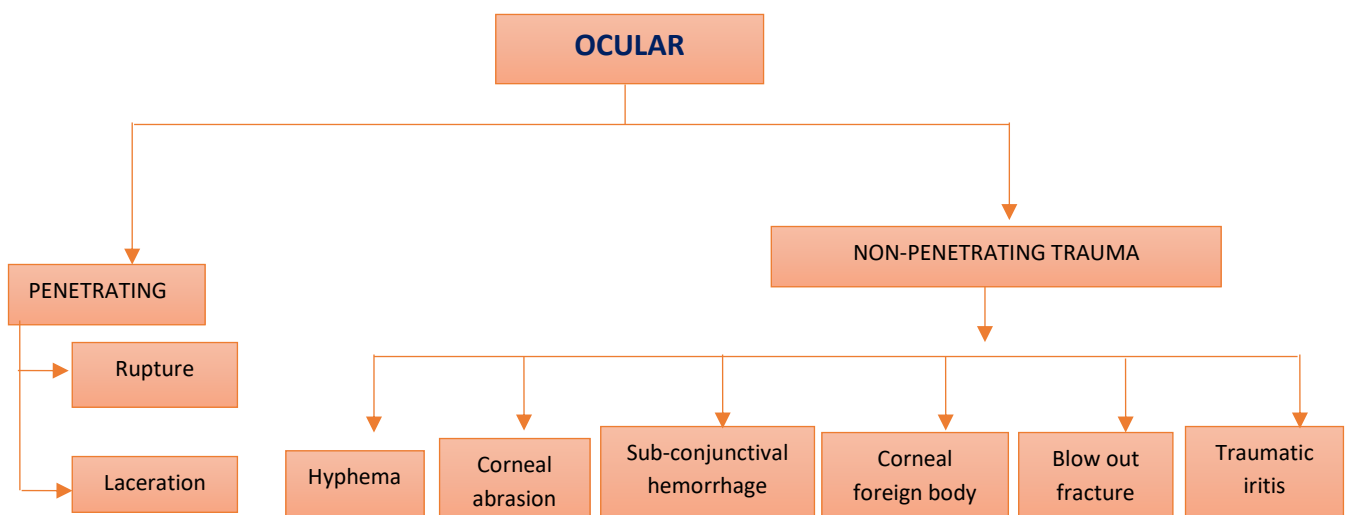
- Topical steroid for the first 7-10 days – to reduce inflammation.
- Topical and systemic tetracycline to inhibit collagenase and neutrophil activity.

### Grading of severity of chemical injuries

<p><b>Grade I</b> (excellent prognosis)</p> <ul style="list-style-type: none"> <li>• Clear cornea</li> <li>• Limbal ischaemia - nil</li> </ul> <p><b>Grade II</b> (good prognosis)</p> <ul style="list-style-type: none"> <li>• Cornea hazy but visible iris details</li> <li>• Limbal ischaemia &lt;1/3</li> </ul> <p><b>Grade III</b> (guarded prognosis)</p> <ul style="list-style-type: none"> <li>• Hazy cornea with no iris details</li> <li>• Limbal ischaemia 1/3 to 1/2</li> </ul> <p><b>Grade IV</b> (very poor prognosis)</p> <ul style="list-style-type: none"> <li>• Opaque cornea</li> <li>• Limbal ischaemia &gt;1/2</li> </ul>	<ul style="list-style-type: none"> <li>• G - II</li> <li>• G - III</li> <li>• G - IV</li> </ul>	
--	---	---

**Figure 13.1** Grading of severity of chemical injuries.

**Follow up-** Grade 1- follow up daily till patient is better. Refer all other cases to the nearest Ophthalmologist.



**Figure 13.2** Flowchart showing ocular trauma.

## CORNEAL LACERATION

Partial-Thickness Laceration

**Signs:** The anterior chamber is not entered and, therefore, the cornea is not perforated.

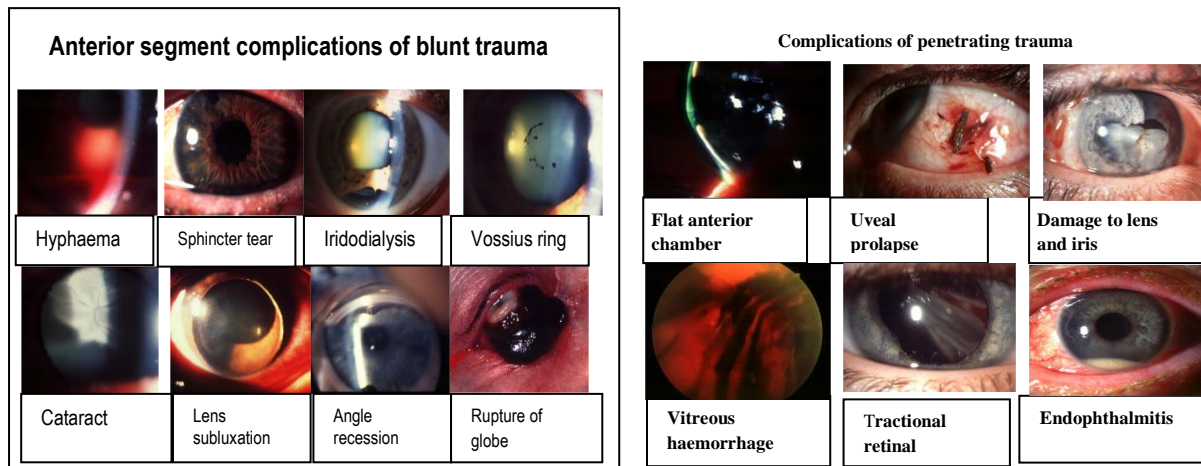
**Work-up:** Careful examination should be performed to exclude ocular penetration. Carefully evaluate the conjunctiva and sclera, checking for extension beyond the limbus in cases involving the corneal periphery.

### Treatment

- An antibiotic (e.g., chloramphenicol or ciprofloxacin) drops 2 hourly for a week, antibiotic ointment and eye pad on the 1<sup>st</sup> day.

- When a moderate to deep corneal laceration is accompanied by wound gape, it may need repair.
- Tetanus toxoid for dirty wounds.
- Refer to the nearest eye center.

**Follow-up:** Reevaluate daily until the epithelium heals.



**Figure 13.3** Pictures showing anterior segment complications of blunt trauma and complications of penetrating ocular trauma.

## RUPTURED GLOBE AND PENETRATING OCULAR INJURY

**Symptoms:** History of trauma, fall, or sharp object entering globe. Pain, decreased vision, loss of fluid from the eye.

**Signs: Critical-** Full-thickness sclera or corneal laceration, severe subconjunctival hemorrhage (especially involving 360 degrees of bulbar conjunctiva, often bullous), a deep or shallow AC compared to the fellow eye, peaked or irregular pupil, iris defects, lens material in the AC, foreign body tract in the lens, or limitation of extraocular motility (greatest in direction of rupture). Intraocular contents may be outside of the globe.

**Other-** Low IOP (although it may be normal or increased), iridodialysis (tear of the iris), hyphema (i.e., clotted blood in AC), periorbital ecchymosis, vitreous hemorrhage, dislocated or sub-luxated lens and traumatic optic neuropathy. Commotio retinae, choroidal rupture, and retinal breaks may be seen but are often obscured by vitreous hemorrhage.

### Work-up and treatment:

Once the diagnosis of a ruptured globe is made, further examination should be deferred until the time of surgical repair in the operating room. This is to avoid placing any pressure on the globe and risking extrusion of intraocular contents. Diagnosis should be made by penlight, or if possible, by slit-lamp examination (with very gentle manipulation). Once the diagnosis is made, then the following measures should be taken:

- Protect the eye with a shield at all times.
- Obtain x-ray of the orbits.
- Place patient on bed rest with bathroom privileges. Avoid bending over and Valsalva maneuvers.
- Systemic antibiotics should be administered within 6 hours of injury. For adults give cefazolin 1 g IV. Q8h or Ciprofloxacin 500mg PO, 200mg IV. b.i.d. For children <12 years, give cefazolin 25 to 50 mg/kg/day IV t.i.d. and gentamycin 2 mg.kg IV q.i.d.

- Administer tetanus toxoid.
- Administer antiemetic (e.g., prochlorperazine 10 mg IM q.i.d. as needed for nausea and vomiting to prevent Valsalva).
- Consider pain medicine.
- Determine the time of the patient's most recent meal.
- Arrange for surgical repair, refer as soon as possible to the nearest ophthalmologist.

## CORNEAL ABRASION

---

It is defined as a defect in the epithelial layer of the cornea. It is superficial and can be caused by minor trauma, foreign bodies, welding light, snow blindness.

**Symptoms** – foreign body sensation, tearing

**Signs** - redness, epithelial defect with fluorescein staining.

**Treatment**- pad with antibiotic eye ointment and a drop of cycloplegic for 24 hours. Systemic analgesics as needed.

**Follow up**- next day and see if the defect has healed. Larger defects may take longer and should be followed up daily.

## CORNEAL AND CONJUNCTIVAL FOREIGN BODIES

---

**Symptoms:** Foreign body sensation, tearing, history of trauma.

**Signs: Critical-** Conjunctival or corneal foreign body with or without rust ring.

**Others-** Conjunctival congestion, eyelid edema, mild AC reaction, and superficial corneal defect. A small infiltrate may surround a corneal foreign body; it is usually sterile. Vertically oriented linear corneal abrasion or may indicate a foreign body under eyelid.

**Work-up-**

- History: Determine the mechanism of injury [e.g., metal striking metal, may suggest an intraocular foreign body (IOFB). Attempt to determine the size, weight, and shape of the object.
- Document visual acuity before any procedure is performed. One or two drops of topical anesthesia may be necessary to control blepharospasm and pain.
- Dilate the eye and examine the posterior segment for a possible IOFB (where possible).

**Note:** *An infiltrate accompanied by a significant AC reaction, purulent discharge, or extreme conjunctival injection and pain should be cultured to rule out an infection, treated aggressively with antibiotics, and followed intensively.*

### Treatment of Corneal foreign body

- Apply topical anesthesia (e.g., xylocaine 4%) before attempting removal of the corneal foreign body with a cotton tip. Multiple superficial foreign bodies may be more easily removed by irrigation.
- Remove the rust ring as completely as possible on the first attempt. It is sometimes safer to leave a deep, central rust ring to allow time for the rust to migrate to corneal surface, at which point it can be removed more easily.
- Treat as for the corneal abrasion.

### Treatment of Conjunctival foreign body

- Remove foreign body under topical anesthesia.
  - Multiple or loose foreign bodies can often be removed with saline irrigation.

- A foreign body can be removed with a cotton-tipped applicator soaked in topical anesthetic or with fine forceps.
- Small, relatively inaccessible, buried subconjunctival foreign bodies may sometimes be left in the eye without harm unless they are infectious or pro inflammatory. Occasionally, they will surface with time, at which point they may be removed more easily.
- Sweep the conjunctival fornices with a glass rod or cotton-tipped applicator soaked with a topical anesthetic to catch any remaining pieces.
- Conjunctival Lacerations exceeding 1 cm need surgical repair.
- A topical antibiotic (e.g., chloramphenicol ointment b.i.d., trimethoprim/polymyxin B or fluoroquinolone drops q.i.d.) may be used.
- Artificial tears (e.g., Refresh q.i.d. for 2 weeks) may be given for irritants.

#### Follow-up-

- **Corneal foreign body:** Follow up as with corneal abrasion. If residual rust ring remains, reevaluate in 24 hours.
- **Conjunctival foreign body:** Follow up as needed, or in one week for residual foreign bodies.

### TRAUMATIC IRITIS

---

**Symptoms:** Dull, aching/throbbing pain, photophobia, tearing, and onset of symptoms within 3 days of trauma.

**Signs: Critical-** White blood cells and flare in the AC (seen under high-power magnification by focusing into the AC with a small, bright beam from the slit lamp.)

**Others-** Pain in the traumatized eye when light enters eye; lower (although sometimes higher) IOP; smaller pupil (which dilates poorly) or larger pupil (caused by iris sphincter tears) in the traumatized eye; circum ciliary conjunctival injection; occasionally, decreased vision.

**Work-up:** Complete ophthalmic examination, including IOP measurement and dilated fundus examination (where possible)

#### Treatment:

Cycloplegics agent (e.g., cyclopentolate 2% 1 to 2 times a day). If the patient is very symptomatic, may use a steroid drop (e.g., prednisolone acetate 0.125% to 1% q.i.d.). Avoid topical steroid if an epithelial defect is present.

#### Follow-up-

- Recheck in 5 to 7 days.
- If resolved, the cycloplegics agent is discontinued and the steroid is tapered.
- In case of worsening or no improvement, refer.

### TRAUMATIC HYPHEMA

---

**Symptoms:** Pain, blurred vision, history of blunt trauma.

**Signs:** Blood or clot or both in the AC, usually visible without a slit-lamp. A total (100%) hyphema may be black or red. When black, it is called an “8-ball” or “black eye” hyphema; when red, the circulating blood cells may settle with time to become less than a 100% hyphema.

#### Work-up-

- History: Mechanism type (blunt vs penetrating) Protective eyewear? Time of injury? Time of visual loss? Usually, a visual compromise occurs at the time of injury; decreasing vision over time suggests a rebleed or continued bleed. Use of medications with anticoagulant properties (aspirin, NASIDs, warfarin,). Symptoms of coagulopathy (e.g., blood nose blowing, bleeding gums with tooth brushing, easy bruising)?
- Ocular examination, first ruling out a ruptured globe. Evaluate for other traumatic injuries. Document the extent (e.g., measure the hyphema height) and location of any clot and blood. Measure the IOP. Perform a dilated retinal evaluation where possible).

**Treatment:** An atraumatic upright environment is essential.

- Confine either to bed rest with bathroom privilege or to limited activity. Elevate head to allow blood to settle.
- Place a shield (metal or clear plastic) over the involved eye at all times. Do not patch because this prevents recognition of sudden loss in the event of rebleed.
- Cycloplegics e.g., Atropine 1% ointment b.i.d. to t.i.d. or homatropine b.i.d. to t.i.d.
- No aspirin-containing products or NASIDs.
- Mild analgesics only (e.g., acetaminophen). Avoid sedatives.
- Use topical steroids (e.g., prednisolone acetate 1% four to eight times per day) if any suggestion of iritis (e.g., photophobia, deep ache, ciliary flush), evidence of lens capsule rupture, any protein (e.g., fibrin), or definitive white blood cells in anterior chamber. Reduce the frequency of steroids as soon as signs and symptoms resolve to reduce the likelihood of steroid-induced glaucoma.

**Note:** *In children particular caution must be used regarding topical steroids. Children often get rapid rise in IOP and with prolonged use there is a significant risk for cataract. As outlined above, in certain cases steroids may be beneficial, but steroid should be prescribed in an individualized manner. Children must be monitored closely for increased IOP and should be tapered off the steroids as soon as possible.*

## ORBITAL BLOW-OUT FRACTURE

**Symptoms:** Pain on attempted eye movement (orbital floor fracture: pain on vertical eye movement: medial wall fracture: pain on ab-/adduction), local tenderness, eyelid edema, binocular diplopia, crepitus after nose blowing, recent history of trauma. Acute tearing is usually due to ocular surface irritations (e.g., conjunctival chemosis, corneal abrasion, iritis).

**Signs: Critical-** Restricted eye movements (especially in upward or lateral gaze or both), subcutaneous or conjunctival emphysema, hypesthesia in the distribution of the infraorbital nerve (i.e., ipsilateral cheek and upper lip), point tenderness, enophthalmos (may initially be masked by orbital edema).

**Other-** Nosebleed, eyelid edema, and ecchymosis. Superior rim and orbital roof fractures may show hypesthesia in the distribution of the supratrochlear or supraorbital nerve (ipsilateral forehead) and ptosis. Trismus, malar flattening, and a palpable step-off deformity of the inferior orbital rim are characteristic of tripod (zygomatic complex) fracture. Optic neuropathy may be present.

### Work-up-

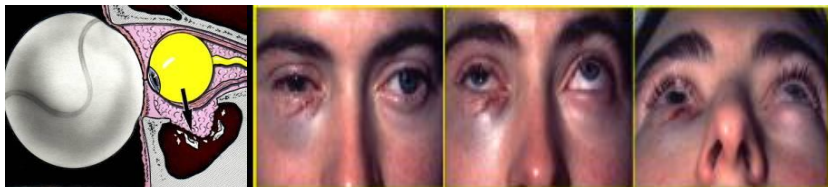- Complete ophthalmologic examination, including measurement of extra ocular movements and globe displacement. Compare the sensation of the affected cheek with that on the contralateral side; palpate the eyelids for crepitus (subcutaneous

emphysema); palpate the orbital rim for step-offs; evaluate the globe carefully for a rupture, hyphema or microhyphaema, traumatic iritis, and retinal or choroidal damage. Measure IOP. Check pupils and color vision to rule out a traumatic neuropathy. If eye and periocular edema limit the view, special techniques may be necessary.

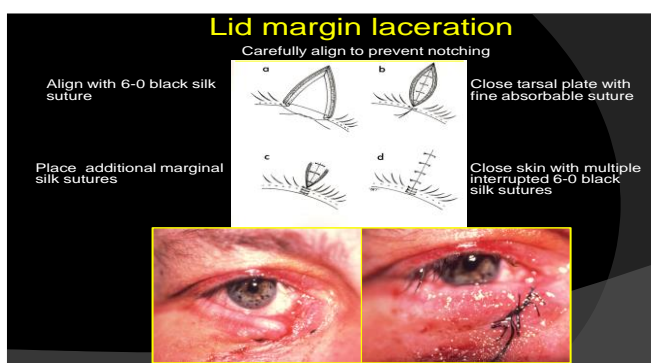
- Forced-duction testing is performed if restriction of eye movement persists beyond one week.
- X-ray of the orbits.
- CT orbit scans are to be obtained in all cases of suspected orbital fractures.

### Treatment

- Broad spectrum oral antibiotics [e.g., cephalexin (250 to 500 mg PO, q.i.d.; or ciprofloxacin 500 mg PO, q.i.d) for 7 days. Antibiotics are recommended if the patient has a history of sinusitis, diabetes, or is otherwise immunocompromised.
- Instruct patient not to blow his/her nose.
- Nasal decongestants [i.e., pseudoephedrine (Afrin) nasal spray b.i.d.] for 3 days. Use is limited to 3 days to minimize the chance of rebound nasal congestion.
- Apply ice packs to the orbit for the first 24 to 48 hours.
- Consider oral steroids if extensive swelling limits examination of ocular motility and globe position. If corticosteroids are used, systemic antibiotics should also be considered.
- Neurosurgical consultation is recommended for all fractures involving the orbital roof, frontal sinus, or cribriform plate and for all fractures associated with intra cranial hemorrhage. Otolaryngology or oral maxillofacial surgery consultation is recommended for frontal sinus, midfacial, and mandibular fractures.
- Surgical repair may be needed depending on severity. Refer.



**Figure 13.4** Pictures showing signs of orbital floor blow-out fracture.



**Figure 13.5** Pictures showing eyelid laceration and suturing.

### ACUTE CONJUNCTIVITIS

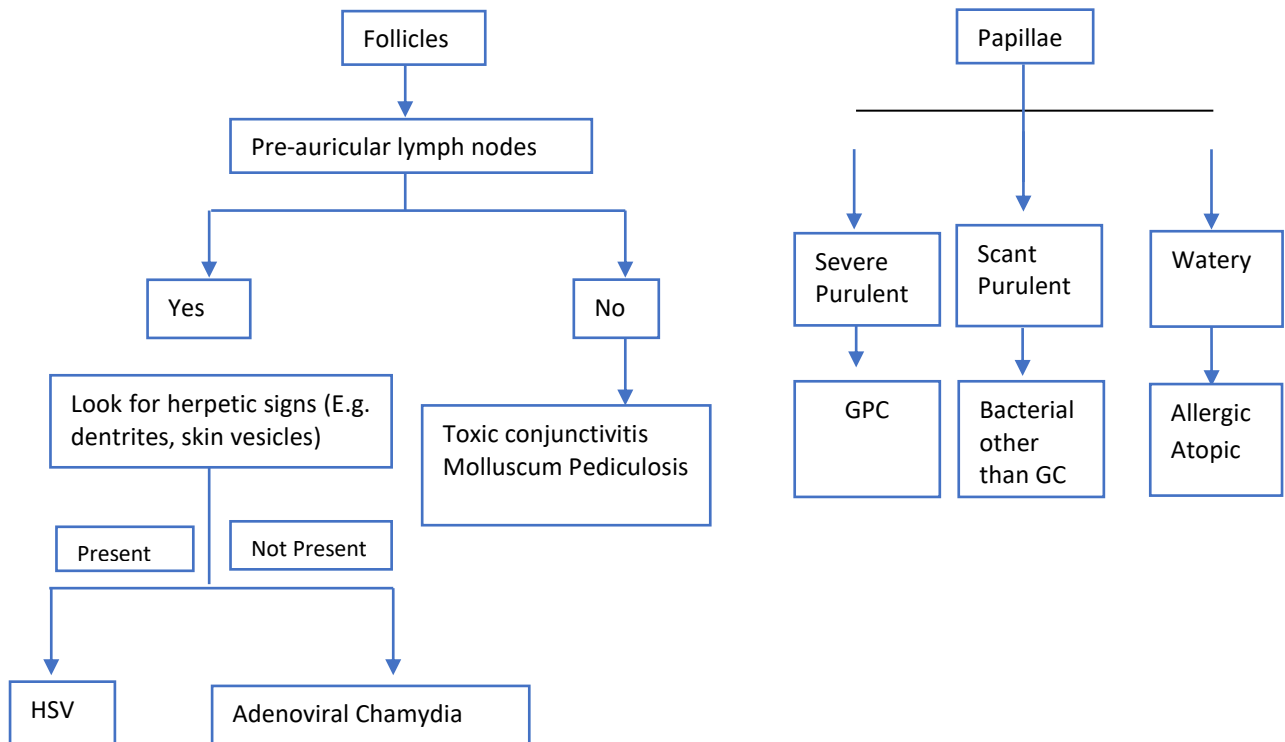
**Signs:** “Red eye” (conjunctival hyperemia), discharge, eyelids sticking (worse in morning), foreign body sensation, less than 4-week duration of symptoms. (Commonly viral more than bacterial)

**Symptoms:** Itching, burning, foreign body sensation; history of recent upper respiratory tract infection or sick contact. Often starts in one eye and involves the fellow eye a few days later.



**Critical-** Inferior palpebral conjunctival follicles, tender palpable preauricular lymph node.

**Other-** Watery discharge, red and edematous eyelids, pinpoint conjunctival haemorrhage, punctuate keratopathy, membrane/ pseudo membrane. Subepithelial infiltrates (SEIs) can develop 1 to 2 weeks after the onset of the conjunctivitis.



**Figure 13.6** Flowchart showing conjunctivitis of various etiologies.

### Etiology of Viral Conjunctivitis:

- Most commonly adenovirus.
- Pharyngoconjunctival fever: Associated with pharyngitis and fever, usually in children.
- Acute hemorrhagic conjunctivitis: Associated with large subconjunctival hemorrhage, coxsackie and entovirus, 1 to 2 weeks duration. Tends to occur in tropical regions.

**Note:** Many systemic viral syndromes (e.g., measles, mumps, and influenza) can cause a non-specific conjunctivitis. The underlying condition should be managed appropriately; the eyes are treated with artificial tears four to eight times per day. If tears are used greater than four times daily, preservative-free unit dose tears should be used.

**Work-up:** No conjunctival cultures/swabs are indicated unless discharge is excessive or the condition becomes chronic.

### Treatment:

- Counsel the patient that viral conjunctivitis is a self-limited condition that typically gets worse for the first 4 to 7 days after onset and may not resolve for 2 to 3 weeks or longer with corneal involvement.
- Viral conjunctivitis is highly contagious, usually for 10 to 12 days from onset as long as the eyes are red (when not on steroids). Patients should avoid touching their eyes, shaking hands, sharing towels, etc. restrict work and school for patients with significant exposure to others while the eyes are weeping.

- Frequent hand washing.
- Preservative-free artificial tears (e.g., Refresh Plus) four to eight times per day for 1 to 3 weeks. Use single-use vials to limit contamination and spread of the condition.
- Cool compress several times a day.
- Antihistamine (e.g., occurs AH 3 to 4 times a day) if itching is severe.
- If the membrane/pseudo membrane present, it may be gently peeled off.
- If the membrane/pseudo membrane, is acutely present or if SEIs reduce vision topical steroid with less frequent dosing is usually sufficient (e.g., fluoromethalone 0.1% b.i.d.). Given the possible side effects, prescription of topical steroids is cautionary in the emergency room setting or in patients with questionable follow-up. Steroid may hasten resolution of the symptoms but prolong the infectious period. Steroid treatment is maintained for 1 week and then slowly tapered.

### ACUTE ANGLE-CLOSURE GLAUCOMA

---

**Symptoms:** Pain, blurred vision, colored halos around lights, frontal headache, and vomiting.

**Signs: Critical.** Closed angle in the involved eye, acutely increased IOP, corneal microcystic edema. Corneal haze. Narrow or occudable angle in the fellow eye if primary etiology.

**Other-** Conjunctival injection; fixed, mid dilated pupil.

#### Etiology of Primary Angle Closure

- Pupillary block: Apposition of the lens and the posterior iris at the pupil leads to blockage of aqueous humor flow from the posterior chamber to the anterior chamber. This mechanism leads to increased posterior chamber pressure, forward movement of the peripheral iris, and subsequent obstruction of the trabecular meshwork. Predisposed eyes have a narrow anterior chamber angle recess, anterior iris insertion of the iris root, or shorter axial length. Risk factor includes increased age, East Asian extraction, female gender, hyperopia, and family history. May be precipitated by topical mydriatic, systemic antipsychotics), accommodation (e.g., reading), or dim illumination. Fellow eye has similar anatomy.
- Angle crowding has a result of an abnormal iris configuration including high peripheral iris roll or plateau iris syndrome angle closure.

**Treatment**— analgesics, Tab acetazolamide 250mg 2 to 4 times a day. Refer immediately.

### DACRYOCYSTITIS/INFLAMMATION OF THE LACRIMAL SAC

---

**Symptoms:** Pain, redness, and swelling over the lacrimal sac in the innermost aspect of the lower eyelid. Also tearing, discharge, or fever. Symptoms may be recurrent.

**Signs: Critical.** Erythematous, tender, tense swelling over the nasal aspect of the lower eyelid and extending around the periorbital area nasally. A mucoid or purulent discharge can be expressed from the punctum when pressure is applied over the lacrimal sac.

**Other.** Fistula formation from the skin beneath the medial canthal tendon. A lacrimal sac cyst or mucocele can occur in chronic cases. Can progress to lacrimal sac abscess, and rarely, orbital or facial cellulitis may develop. May have a chronic mucopurulent conjunctivitis.

#### Etiology

- Almost always related to nasolacrimal duct obstruction.
- Less commonly due to diverticula of the lacrimal sac, dacryoliths, nasal or sinus surgery, trauma, or rarely, a lacrimal sac tumor.

- Most common organism: staphylococci, streptococci, and diphtheroid.

**Work-up-**

- History: Previous episodes? Concomitant ear, nose, or throat infection?
- External examination: Apply gentle pressure to the lacrimal sac in the nasal corner of the lower eyelid with a cotton-tipped swab in an attempt to express discharge from the punctum.
- Ocular examination: Assess extraocular motility and for proptosis for evidence of orbital cellulitis.
- Obtain a Gram stain and blood agar culture (and chocolate agar culture in children) of any discharge expressed from the punctum.

**Treatment:**

- Systemic antibiotics in the following regimen:

**Children:**

- **Afebrile**, systemically well, mild case and reliable parent. Amoxicillin/clavulanate (e.g., Augmentin) 20 to 40 mg/kg/day PO in three divided doses.
- **Febrile**, acutely ill, moderate to severe cases, or unreliable parent: Hospitalize and treat with cefuroxime, 50 to 100 mg/kg/day intravenously (IV) in three divided doses.

**Adults:**

- **Afebrile**, systemically well, mild cases, and reliable patients, Cephalexin (e.g., Keflex) 500mg PO, q6h. Alternative treatment: Amoxicillin/clavulanate (e.g., Augmentin) 500 mg PO, q8h
- **Febrile**, acutely ill, Hospitalize and treat with cefazolin 1 g IV q8h
- Topical antibiotic drops may be used in addition to systemic therapy. Topical therapy alone is not adequate.
- Apply warm compresses and gentle massage to the inner canthal region q.i.d.
- Administer pain medication (e.g., acetaminophen with or without codeine) as needed.
- Consider incision and drainage of a pointing abscess.
- Surgical correction (e.g., dacryocystorhinostomy with or without silicone intubation) is usually needed once the acute episode has resolved, particularly with chronic dacryocystitis.

**Follow-up:** Daily until improvement confirmed. If the condition of an outpatient worsens, hospitalization and IV antibiotics are recommended.

**References**

1. Principle and Practice of Ophthalmology by Albert and Jakobiec.
2. OPHTHALMOLOGY by Yanoff and Duker.
3. Clinical Ophthalmology by Kanski.